

# Diagnosis and Treatment of First Metatarsophalangeal Joint Disorders.

## Section 3: Hallux Varus

**Clinical Practice Guideline First Metatarsophalangeal Joint Disorders Panel:**  
**John V. Vanore, DPM,<sup>1</sup> Jeffrey C. Christensen, DPM,<sup>2</sup> Steven R. Kravitz, DPM,<sup>3</sup>**  
**John M. Schuberth, DPM,<sup>4</sup> James L. Thomas, DPM,<sup>5</sup> Lowell Scott Weil, DPM,<sup>6</sup>**  
**Howard J. Zlotoff, DPM,<sup>7</sup> and Susan D. Couture<sup>8</sup>**

This clinical practice guideline (CPG) is based upon consensus of current clinical practice and review of the clinical literature. The guideline was developed by the Clinical Practice Guideline First Metatarsophalangeal (MTP) Joint Disorders Panel of the American College of Foot and Ankle Surgeons. The guideline and references annotate each node of the corresponding pathways.

### Hallux Varus Deformity (Pathway 4)

Hallux varus is a deformity of the great toe that is characterized by adduction of the hallux and medial subluxation of the first MTP joint.

#### Significant History (Node 1)

Patients presenting with a hallux varus deformity usually have a history of previous first MTP joint or bunion surgery (1–6). The abnormal position of the toe makes wearing shoes difficult and painful. This often is a progressive deformity and may lead to a severe, disfiguring, and complex condition. Many patients present because of the cosmetic disfigurement of the toe and foot.

Hallux varus is usually a postoperative complication after bunion surgery (1,7–13). Other causes may include congenital (14–19) or idiopathic variants (20,21), inflammatory arthritides (4,22,23), posttraumatic causes (24–27), association with complex congenital deformities such as clubfoot deformity or polydactyly (15,28,29), or secondary to neuromuscular disorders (30–32) (Node 2).

<sup>1</sup> Chair, Gadsden, AL; <sup>2</sup> Everett, WA; <sup>3</sup> Richboro, PA; <sup>4</sup> San Francisco, CA; <sup>5</sup> Board Liaison, Birmingham, AL; <sup>6</sup> Des Plaines, IL; <sup>7</sup> Camp Hill, PA; and <sup>8</sup> Park Ridge, IL. Address correspondence to: John V. Vanore, DPM, Gadsden Foot Clinic, 306 South 4th St, Gadsden, AL 35901; e-mail: jvanore@prodigy.net

Copyright © 2003 by the American College of Foot and Ankle Surgeons  
1067-2516/03/4203-0004\$30.00/0  
doi:10.1053/jfas.2003.50038

#### Significant Findings (Node 3)

Hallux varus is a deformity of the great toe that manifests as a medial displacement of the first MTP joint. This malalignment can occur purely on the transverse plane with adduction of the hallux or can occur in combination with deformity on the frontal plane and/or sagittal plane (2). Patients who develop hallux varus may possess a long hallux and/or first ray (6). A loss of toe purchase occurs as a hallux hammertoe develops, often resulting in irritation and bursitis at the hallucal interphalangeal joint (IPJ).

#### Associated Findings (Node 4)

Progressive adduction of the great toe influences the lesser toes, which may also develop severe adductus (11). The forefoot deformity may result in compensatory rear-foot supination with lateral metatarsal overload. Shoe pressure on the adducted great toe may result in an ingrown toenail.

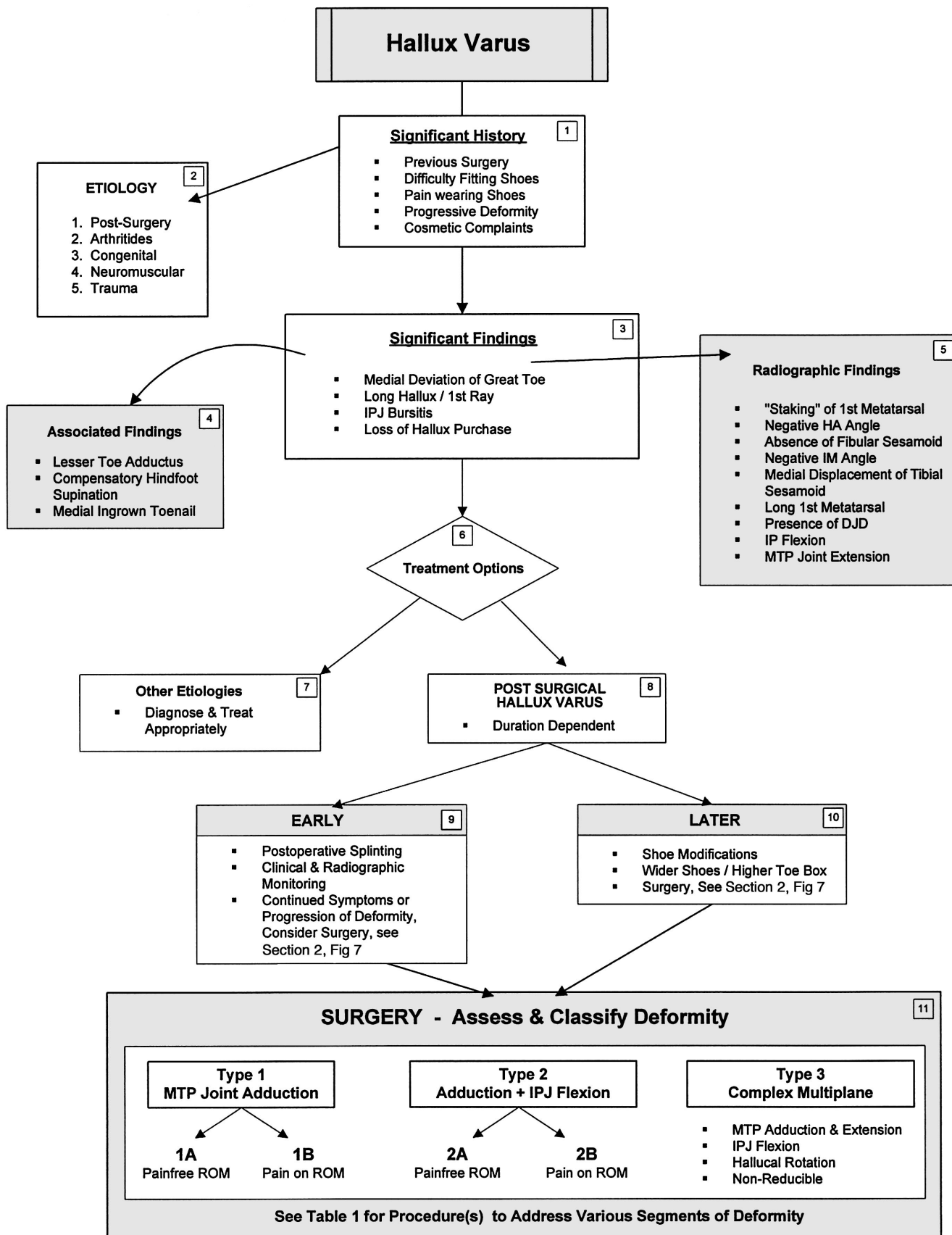
#### Radiographic Findings (Node 5)

Hallux varus presents with a unique set of radiographic findings that characterize the development and complexity of the individual deformity. Findings may include:

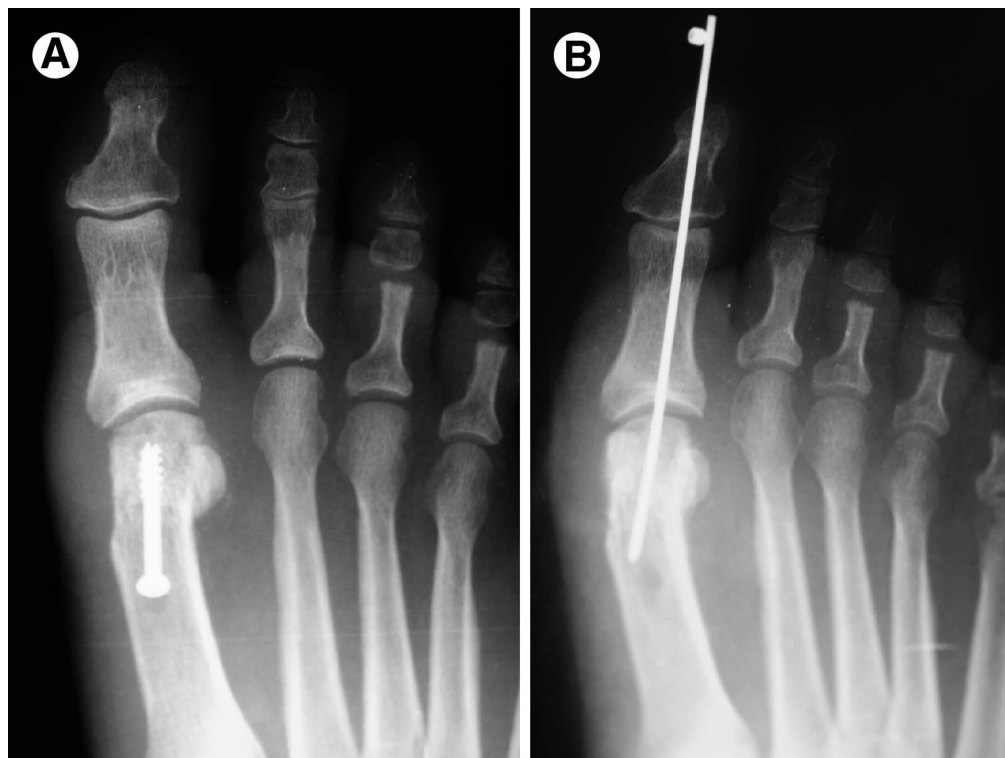
- Staking of the medial metatarsal head (6,33)
- Negative hallux abductus angle (1)
- Absence of fibular sesamoid (surgical excision) (7,8)
- Negative intermetatarsal angle (34)
- Medial subluxation of the tibial sesamoid (35)
- IPJ flexion ± MTP joint extension (33)
- Presence of degenerative joint disease (2,33)
- Long first metatarsal (6)

#### Treatment of Hallux Varus (Node 6)

Treatment options of hallux varus are dependent on the cause and the complexity of deformity. Congenital varieties



Pathway 4



**FIGURE 1** Type 1A hallux varus treated with (A) total joint release and (B) Kirschner wire stabilization.

may be asymptomatic and may require little intervention (Node 7). Treatment of postsurgical hallux varus may vary considerably and is predicated on the patient's symptoms, the degree of deformity, and the amount of time after surgery (10) (Node 8).

#### Early Postsurgical Hallux Varus (Node 9)

In the initial stage of hallux varus, splinting may have a beneficial influence but is not effective as the deformity matures. Patients should be monitored both clinically and radiographically to assess progression. If reduction is not apparent, or if increasing severity is noted, patients may require prompting to correct the deformity at an early stage.

#### Late Postsurgical Hallux Varus (Node 10)

As the deformity evolves, hallux varus becomes more difficult to correct. Although progression of the deformity may be quite striking, patients may have a high clinical tolerance of the deformity.

Nonsurgical treatments include wider shoes with a deep toe box. Surgical treatment is tailored to the degree and complexity of deformity. Maturation generally yields soft tissue contraction, increasing severity of deformity, and complex forefoot malalignments, which may result long term in joint arthrosis.

#### Classification (Node 11)

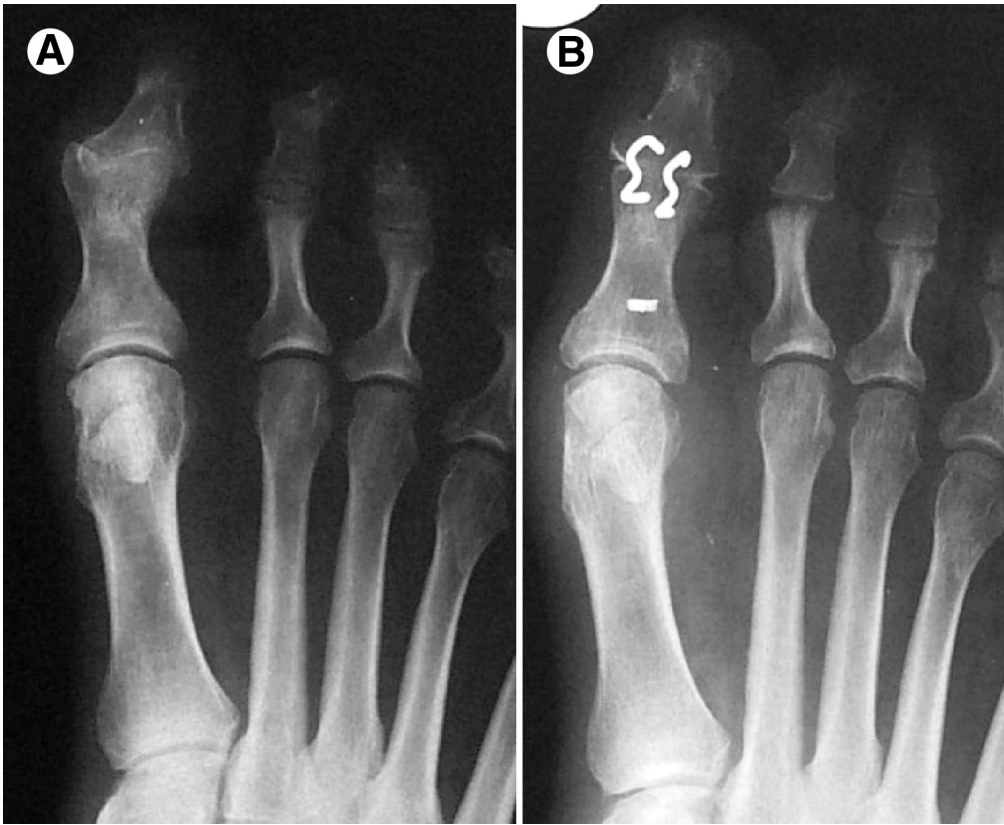
Recommendations for surgical treatment are based on the following arbitrary classification:

- Type 1—MTP adduction: 1A, deformity alone; 1B, deformity plus arthrosis
- Type 2—MTP adduction plus IPJ flexion: 2A, deformity alone; 2B, deformity plus arthrosis
- Type 3—Complex multiplanar deformity

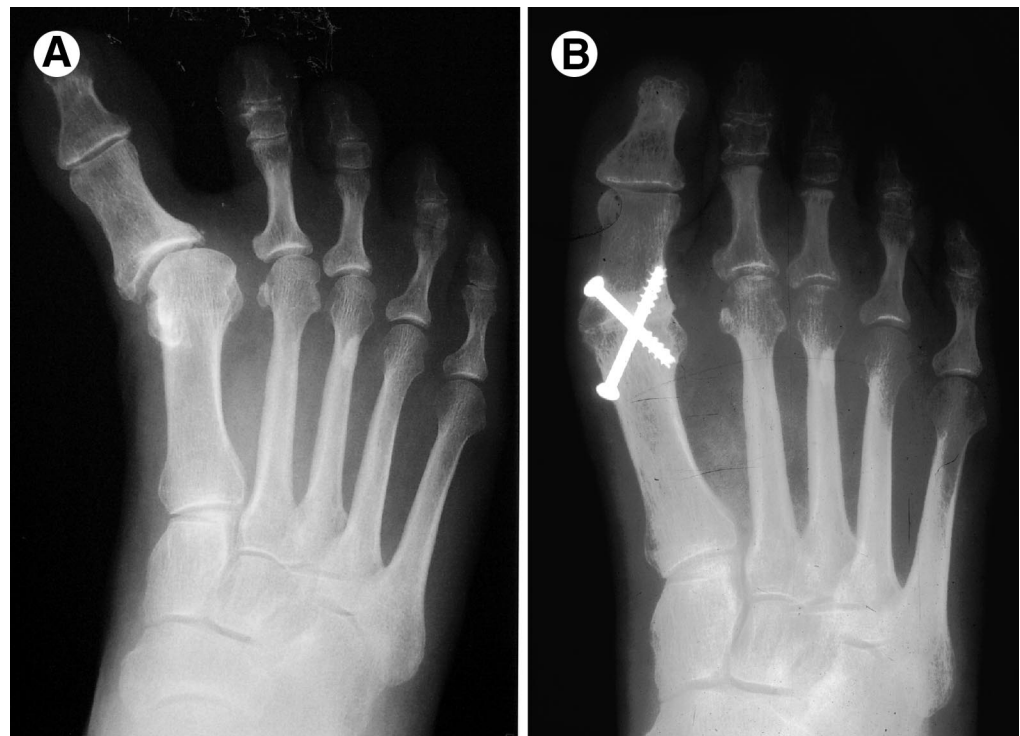
**Type 1.** Hallux varus, in its simplest form, is characterized by the adducted position of the great toe. Range of motion may be full and pain free (1A), or may become painful and limited as arthrosis progresses (1B). The deformity may be reducible or may show varied degrees of rigidity (Fig. 1).

**Type 2.** Hallux stability is lost, and flexion of the IPJ complicates the transverse plane deformity at the MTP joint. Range of motion may be full and pain free (2A), or may become painful and limited as arthrosis progresses (2B). These deformities may be reducible with manual manipulation but are difficult to maintain with simple soft tissue release (Fig. 2).

**Type 3.** These complex deformities have a combination of transverse, sagittal, and frontal plane abnormalities, generally combined with arthritic degeneration. Hallux purchase is lost with extensus, hammering, and rotation of the



**FIGURE 2** (A) Type 2A hallux varus with characteristic IPJ flexion. (B) Preoperative anteroposterior radiograph shows treatment with IPJ fusion, total joint release, and extensor hallucis longus tendon transfer.



**FIGURE 3** (A) Severe complex hallux varus deformity (type 3) treated with (B) first MTP joint fusion.

**TABLE 1 Surgical options: hallux varus**

| Surgical Procedure (Reference)          | Type 1 |    | Type 2 |    | Type 3 |
|---|--------|----|--------|----|--------|
|   | 1A     | 1B | 2A     | 2B |        |
| Percutaneous K-wire                     | +      |    |        |    |        |
| Joint release and repair (13,36)        | ++     | +  | ++     | +  | +      |
| Abductor hallucis release (37,38)       | ++     | +  | ++     | +  | +      |
| EHL transfer (Johnson) (12,13,24,39,40) |        |    |        |    | ++     |
| EHL lengthening (35)                    |        |    |        |    | ++     |
| Jones suspension                        |        |    | +      | +  | +      |
| Excision tibial sesamoid (12,35)        | +      | +  | +      | +  | +      |
| IPJ arthrodesis/arthroplasty (13,41)    |        |    |        |    | ++     |
| Phalangeal osteotomy (42)               | +      | +  | +      | +  |        |
| Metatarsal osteotomy (43)               | +      | +  | +      | +  | +      |
| Resection arthroplasty                  |        | ++ |        | ++ |        |
| Hinge toe implant (44)                  |        | ++ |        | ++ |        |
| MTP joint arthrodesis (9,13,14,45)      |        | ++ |        | ++ | ++     |

NOTE. +, appropriate; ++, ideal surgical procedure.

Abbreviations: EHL, extensor hallucis longus; K-wire, Kirschner wire.

digit (Fig. 3). This deformity is usually symptomatic and nonreducible. Irritation from shoe gear is common.

Surgical treatment is based on this classification and is described in Table 1.

### Summary

Hallux varus can be congenital or iatrogenic; successful management and treatment are dependent on a comprehensive evaluation of the deformity. Conservative and surgical management of hallux varus has been discussed, with the ultimate goal of relieving symptoms and reestablishing a functional joint.

### References

1. Banks AS, Ruch JA, Kalish SR. Surgical repair of hallux varus. *J Am Podiatr Med Assoc* 78:339–334, 1988.
2. Donley BG. Acquired hallux varus. *Foot Ankle Int* 18:586–592, 1997.
3. Edelman RD. Iatrogenically induced hallux varus. *Clin Podiatr Med Surg* 8:367–382, 1991.
4. Granberry WM, Hickey CH. Idiopathic adult hallux varus. *Foot Ankle Int* 15:197–205, 1994.
5. Greenfogel SI, Glubo S, Werner J, Sherman M, Lenet M. Hallux varus—surgical correction and review of the literature. *J Foot Surg* 23:46–50, 1984.
6. Janis LR, Donick II. The etiology of hallux varus: a review. *J Am Podiatry Assoc* 65:233–237, 1975.
7. Hawkins FB. Acquired hallux varus: cause, prevention and correction. *Clin Orthop* 76:169–176, 1971.
8. Turner RS. Dynamic post-surgical hallux varus after lateral sesamoidectomy: treatment and prevention. *Orthopedics* 9:963–969, 1986.
9. Tourne Y, Saragaglia D, Picard F, De Sousa B, Montbarbon E, Charbel A. Iatrogenic hallux varus surgical procedure: a study of 14 cases. *Foot Ankle Int* 16:457–463, 1995.
10. Trnka HJ, Zettl R, Hungerford M, Muhlbauer M, Ritschl P. Acquired hallux varus and clinical tolerability. *Foot Ankle Int* 18:593–597, 1997.

11. Miller JW. Acquired hallux varus: a preventable and correctable disorder. *J Bone Joint Surg* 57A:183–188, 1975.
12. Johnson KA, Spiegl PV. Extensor hallucis longus transfer for hallux varus deformity. *J Bone Joint Surg* 66A:681–686, 1984.
13. Skalley TC, Myerson MS. The operative treatment of acquired hallux varus. *Clin Orthop* 306:183–191, 1994.
14. Mills JA, Menelaus MB. Hallux varus. *J Bone Joint Surg* 71B:437–440, 1989.
15. Vispo-Seara JL, Krauspe R. Hallux varus congenitus. *Z Orthop Ihre Grenzgeb* 136:542–547, 1998.
16. Sobel E, Levitz S, Cohen R, Giorgini R, Jules KT. Longitudinal epiphyseal bracket: associated foot deformities with implications for treatment. *J Am Podiatr Med Assoc* 86:147–155, 1996.
17. Wright SM. Congenital hallux varus deformity with bilateral absence of the hallucal sesamoids. *J Am Podiatr Med Assoc* 88:47–48, 1998.
18. Neil MJ, Conacher C. Bilateral delta phalanx of the proximal phalanges of the great toes. A report on an affected family. *J Bone Joint Surg* 66B:77–80, 1984.
19. Andrisano A, Cardelicchio R, Cosco F. Congenital hallux varus: surgical treatment. *Chir Organi Mov* 68:731–737, 1982.
20. Joseph B, Jacob T, Chacko V. Hallux varus—a study of thirty cases. *J Foot Surg* 23:392–397, 1984.
21. Davies MS, Parker BC. Idiopathic hallux varus. *Foot Ankle Int* 16:210–211, 1995.
22. Gould N. Surgery of the forepart of the foot in rheumatoid arthritis. *Foot Ankle* 3:173–180, 1982.
23. Joseph B, Chacko V, Abraham T, Jacob M. Pathomechanics of congenital and acquired hallux varus: a clinical and anatomical study. *Foot Ankle* 8:137–143, 1987.
24. Hunter WN, Wasiak GA. Traumatic hallux varus correction via split extensor tenodesis. *J Foot Surg* 23:321–325, 1984.
25. Labovitz JM, Kaczander BI. Traumatic hallux varus repair utilizing a soft-tissue anchor: a case report. *J Foot Ankle Surg* 39:120–123, 2000.
26. Saraiya H. Post-burn hallux varus: a case report and management of a rare deformity. *Burns* 26:593–598, 2000.
27. Mullis DL, Miller WE. A disabling sports injury of the great toe. *Foot Ankle* 1:22–25, 1980.
28. Masada K, Tsuyuguchi Y, Kawabata H, Ono K. Treatment of preaxial polydactyly of the foot. *Plast Reconstr Surg* 79:251–258, 1987.
29. Phelps DA, Grogan DP. Polydactyly of the foot. *J Pediatr Orthop* 5:446–451, 1985.
30. Jahss MH. Spontaneous hallux varus: relation to poliomyelitis and

- congenital absence of the fibular sesamoid. *Foot Ankle* 3:224–226, 1983.
31. Morita S, Muneta T, Yamamoto H, Shinomiya K. Tendon transfer for equinovarus deformed foot caused by cerebrovascular disease. *Clin Orthop* 350:166–173, 1998.
  32. Herva R, Seppanen U. Roentgenologic findings of the hydrolethalus syndrome. *Pediatr Radiol* 14:41–43, 1984.
  33. Yu GV, Judge M, Shook JE. Complications of hallux abducto valgus surgery. In *McGlamry's Comprehensive Textbook of Foot and Ankle Surgery*, 3rd ed, pp 655–677, edited by AS Banks, DE Martin, SJ Miller, Lippincott, Philadelphia, 2001.
  34. Youngswick FD. Iatrogenic hallux varus. In *Textbook of Bunion Surgery*, pp 493–508, edited by J Gerbert, Futura, Mount Kisco, NY, 1991.
  35. Boike AM, Christein G. Hallux varus. In *Hallux Valgus and Forefoot Surgery*, pp 307–312, edited by VJ Hetherington, Churchill Livingstone, New York, 1994.
  36. Wood WA. Acquired hallux varus: a new corrective procedure. *J Foot Surg* 20:194–197, 1981.
  37. McBride ED. The conservative operation for “bunions.” End results and refinements of technique. *J Am Med Assoc* 105:1164–1168, 1935.
  38. Clark WD. Abductor hallucis tendon transfer for hallux varus. *J Foot Surg* 23:146–148, 1984.
  39. Goldman FD, Siegel J, Barton E. Extensor hallucis longus tendon transfer for correction of hallux varus. *J Foot Ankle Surg* 32:126–131, 1993.
  40. Maynou C, Beltrand E, Podglajen J, Elise S, Mestdagh H. Tendon transfers in postoperative hallux varus. Apropos of 12 cases. *Rev Chir Orthop Reparatrice Appar Mot* 86:181–187, 2000.
  41. Langford JH, Maxwell JR. A treatment for postsurgical hallux varus. *J Am Podiatry Assoc* 72:142–144, 1982.
  42. Weil S, Lowell Scott. Reverse Akin for hallux varus. Poster presented at: American College of Foot and Ankle Surgeons Annual Meeting; San Francisco; February 13–16, 1993.
  43. Bilotti MA, Caprioli R, Testa J, Cournoyer R, Esposito FJ. Reverse Austin osteotomy for correction of hallux varus. *J Foot Surg* 26:51–55, 1987.
  44. Andreasi A. Treatment of iatrogenic hallux varus by arthrodesis of the first metatarsophalangeal joint. *Arch Putti Chir Organi Mov* 36:123–135, 1986.